

Journal of Dermatological Case Reports

Reticular Oral Lichen Planus in a Stress-Associated Female Patient: A Clinico-Pathological Case Report

Dr. Myla Swathi¹, Dr. Saladi Sai Durga Likhitha², Kamepalli. Vani Komali³, Kambala Nandini⁴, Kamapantula Sri Samavita⁵

¹Reader, Department of Oral Medicine & Radiology, St Joseph Dental College, Duggirala, Eluru District, Andhra Pradesh, India

²Post Graduate, Department of Oral Medicine & Radiology, St Joseph Dental College, Duggirala, Eluru District, Andhra Pradesh, India

^{3,4,5}Intern, St Joseph Dental College, Duggirala, Eluru District, Andhra Pradesh, India

Corresponding Author

Dr. Saladi Sai Durga Likhitha

Post Graduate, Department of Oral Medicine & Radiology, St Joseph Dental College, Duggirala, Eluru District, Andhra Pradesh, India

Email: omrdsjdc@gmail.com

Keywords:

Oral Lichen Planus, Reticular Lichen Planus, Wickham's Striae, Buccal Mucosa, Psychological Stress, Potentially Malignant Disorder, Histopathology

Abstract:

Background: Oral lichen planus (OLP) is a chronic immune-mediated mucocutaneous disorder affecting approximately 0.5–2% of the population and is recognized as a potentially malignant disorder. The reticular variant is the most common clinical form and is characterized by the presence of Wickham's striae. Psychological stress has been implicated as an important precipitating and exacerbating factor in the pathogenesis of OLP.

Case Presentation: A 38-year-old female presented with a 10-year history of asymptomatic white striations on the left buccal mucosa. Clinical examination revealed a well-defined whitish-grey lesion measuring approximately 3.0 × 2.0 cm, exhibiting fine, lace-like reticular striae characteristic of Wickham's striae. The lesion was non-tender, non-indurated, and showed no evidence of ulceration, erosion, or surrounding erythema. The patient reported a prolonged history of chronic psychosocial stress. An incisional biopsy was performed, and histopathological examination demonstrated parakeratinized stratified squamous epithelium with focal epithelial-connective tissue separation and a dense juxtaepithelial lymphocytic inflammatory infiltrate, confirming the diagnosis of reticular oral lichen planus.

Discussion: The clinical and histopathological findings were consistent with classical reticular OLP. Chronic psychological stress may have contributed to disease initiation and persistence through neuroendocrine-immune interactions and immune dysregulation. As the lesion was asymptomatic, conservative management with patient education, stress reduction measures, and periodic follow-up was advised.

Conclusion: This case highlights the importance of comprehensive clinical examination and histopathological confirmation in the diagnosis of oral white lesions. Early recognition of OLP, assessment of potential risk factors such as psychological stress, and long-term surveillance are essential because of its potential for malignant transformation.

Introduction

Oral lichen planus (OLP) is a chronic, recurrent, immune-mediated mucocutaneous disorder first described by Wilson in 1869.¹ It ranks among the most prevalent non-infectious conditions of the oral mucosa, affecting approximately 0.5–2.0% of the general population worldwide.² The disease demonstrates a distinctive female predilection, with a female-to-male ratio of approximately 2:1, and most commonly manifests in the fourth to sixth decades of

life.³ Oral lichen planus may present in multiple clinical forms, including reticular, erosive, atrophic, papular, plaque-like, and bullous variants. Of these, the reticular form—characterized by interlacing white striae known as Wickham's striae—is the most frequently encountered and is pathognomonic when identified on the buccal mucosa.⁴ The aetiopathogenesis of OLP remains incompletely elucidated; however, a substantial body of evidence implicates a T-cell-mediated autoimmune mechanism

in which CD8⁺ cytotoxic lymphocytes trigger keratinocyte apoptosis at the epithelial–connective tissue interface.⁵ Psychological stress has been extensively investigated as a significant precipitating and exacerbating factor, modulating immune responses via hypothalamic–pituitary–adrenal (HPA) axis dysregulation and subsequent neuroendocrine–immune interactions.⁶ The World Health Organization (WHO) has categorized OLP as a potentially malignant disorder (PMD), with a reported malignant transformation rate of 0.4–3.7%, necessitating regular long-term surveillance.⁷ A confirmed histopathological diagnosis via incisional biopsy remains the gold standard, complementing the clinical assessment to guide patient management.⁸ The present case report describes the clinical and histopathological findings of a 38-year-old female patient presenting with reticular oral lichen planus of the left buccal mucosa with a decade-long history of chronic psychosocial stress, emphasizing the role of systematic clinical examination and biopsy in establishing a definitive diagnosis.

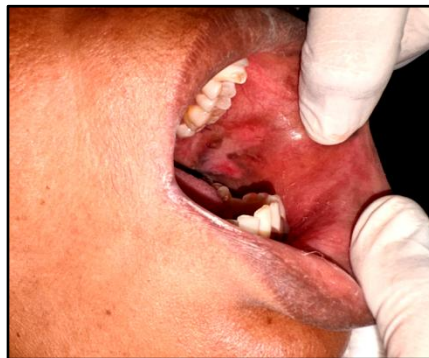Case Report

Patient History

A 38-year-old female patient reported to the Department of Oral Medicine and Radiology with a chief complaint of white striations on the inner cheek (left side) for approximately 10 years. The onset was insidious, and the lesions were non-progressive in recent months. The patient denied any associated pain, burning sensation, or difficulty in mastication at the time of presentation.

Intraoral Examination

On inspection, intraoral inspection was performed with proper cheek retraction. The hard and soft palate, floor of the mouth, tongue (dorsal, ventral, and lateral surfaces), labial mucosa, gingival tissues, and right buccal mucosa were within normal limits. A well-defined area of interlacing white striae (Wickham's striae) was observed on the left buccal mucosa. The lesions appeared as fine, lace-like, whitish-grey linear striations arranged in a reticular (net-like) pattern. The striae were bilateral and confluent in the mid-buccal zone, with no associated ulceration, erosion, or bullae formation.



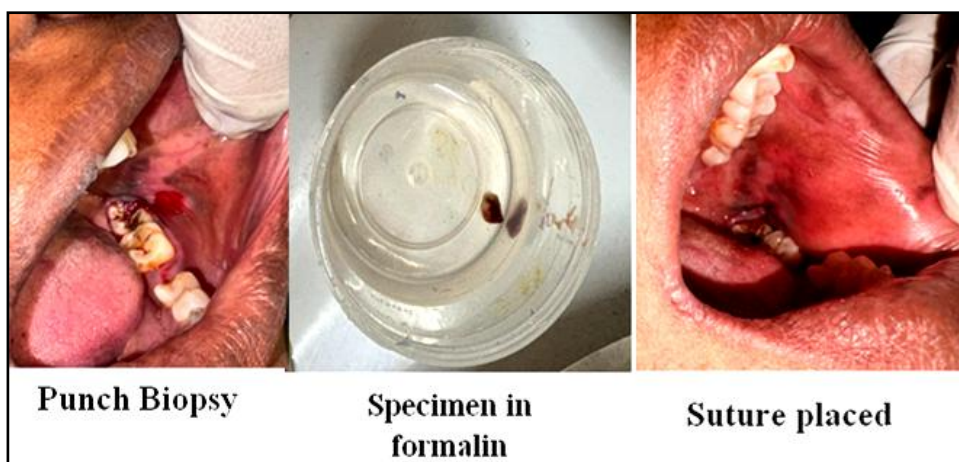
The above picture shows Erosive Lichen planus involving left buccal mucosa

On clinical examination, a whitish-grey lesion was observed on the **left buccal mucosa**, involving the **mid and posterior third** of the mucosal surface. The lesion measured approximately **3.0 cm anteroposteriorly**, extending from the level of the **upper canine region posteriorly to the upper second premolar**, and approximately **2.0 cm superoinferiorly**, extending from the **occlusal plane superiorly to about 2 cm below the occlusal line**. Laterally, the lesion was confined to the **mid-buccal zone** and did not extend to the **oral commissure or retromolar region**. It appeared **whitish-grey in color**

and exhibited **fine, lace-like, interlacing reticular striae characteristic of Wickham's striae**. The borders were **well defined**, although the margins gradually blended with the adjacent normal mucosa. There was **no evidence of ulceration, erosion, bullae, or surrounding erythema** at the time of examination. On palpation the mucosal surface felt smooth and slightly raised over the striate area. The underlying buccal mucosa is without induration. The lesion was non-tender on gentle digital palpation. No spontaneous bleeding was elicited on probing or palpation of the striae. There was no evidence of deep

induration, which would raise suspicion for malignant transformation. with reactive, not pathological, enlargement. Pt underwent Incisional Biopsy (Punch)

in Department of Oral Medicine & Radiology, St. Joseph Dental College, Eluru.



Histopathology Report

The given H&E stained shows parakeratinised stratified squamous epithelium with focal areas showing split in the epithelial connective tissue interface. Underlying connective tissue shows dense chronic inflammatory infiltrate with lymphocytes predominantly at the juxta epithelial region. Endothelial lined blood capillaries and extravasated RBC s are seen. These features are responsible for lichen planus, this report is given in St. Joseph Dental College, Eluru.

Discussion

The present case exemplifies the classical clinical and histopathological presentation of reticular oral lichen planus in a middle-aged female patient with a long-standing history of chronic psychosocial stress. The temporal correlation between stress onset and lesion appearance is consistent with the well-established stress-OLP nexus.⁶ Lichen planus of the oral mucosa is fundamentally a T-lymphocyte-mediated autoimmune disorder. In the disease process, activated CD4⁺ and CD8⁺ T-lymphocytes recognize unidentified antigenic peptides presented by basal keratinocytes, culminating in antigen-specific and non-specific keratinocyte apoptosis via perforin, granzyme-B, and Fas-FasL pathways.⁵ This immune cascade is reflected in the hallmark histopathological feature of a band-like sub-epithelial lymphocytic infiltrate, as observed in our biopsy specimen. Psychological stress plays a multifaceted immunomodulatory role in OLP. Stress-induced

activation of the HPA axis leads to elevated cortisol levels, which paradoxically enhance pro-inflammatory cytokine production (TNF- α , IL-6, IL-17) in the context of chronic immune dysregulation.⁶ Additionally, stress activates the sympathetic nervous system, increasing catecholamine release, which upregulates the expression of adhesion molecules and chemokines that facilitate lymphocytic trafficking to mucosal tissues.⁹ Neuropeptides such as substance P and calcitonin gene-related peptide (CGRP), released from cutaneous and mucosal nerve fibers during stress, further amplify local inflammation.¹⁰ Clinically, the reticular form of OLP—as in our patient—is characterized by Wickham's striae: fine, interlacing white lines or striae forming a lace-like network.⁴ The buccal mucosa is the most commonly affected site, followed by the tongue, gingival tissues, and labial mucosa.¹¹ A systematic approach to intraoral inspection, documenting the anteroposterior and superoinferior extent precisely (as tabulated in Table 1), is paramount for monitoring disease progression or remission over time. The characteristically non-tender, freely mobile, non-indurated consistency on palpation in our patient, combined with the absence of ulceration or erythema, is consistent with the reticular (least symptomatic) OLP subtype.⁴ Had induration, fixation, or irregular ulceration been detected, an elevated index of suspicion for malignant transformation would have been warranted, and additional investigations such as direct immunofluorescence (DIF), toluidine blue vital staining, punch biopsy cytology would have been

considered.¹² Management of OLP is primarily directed at symptom control and immune suppression. For asymptomatic reticular OLP, as in our case, a conservative approach comprising patient education, stress management counselling, and regular follow-up is appropriate. Topical corticosteroids (clobetasol propionate 0.05% gel or fluocinolone acetonide 0.1% solution) remain the mainstay of pharmacological therapy for symptomatic variants; systemic immunosuppressants (prednisolone, azathioprine) are reserved for severe or recalcitrant cases.¹⁶ Psychological counseling and stress reduction strategies (cognitive behavioral therapy, mindfulness-based stress reduction) addressing the identified etiological stress trigger in our patient are also strongly recommended.¹⁷

Conclusion

This case of reticular oral lichen planus in a 38-year-old female with chronic psychosocial stress of 10 years' duration highlights the indispensable value of a meticulous, structured clinical examination—encompassing precise documentation of the anteroposterior and superoinferior extent by inspection, and careful bidigital palpation to assess consistency, tenderness, and mobility—in the workup of white oral mucosal lesions. The histopathological confirmation via incisional biopsy, yielding the pathognomonic triad of OLP, underscores that biopsy remains the definitive diagnostic tool. Clinicians must maintain heightened vigilance for malignant transformation and institute a robust, long-term follow-up protocol for all patients diagnosed with this potentially malignant disorder. Addressing the psychosocial aetiology through targeted stress management strategies constitutes an integral component of holistic patient care.

References

1. Wilson E. On leichen planus. *J Cutan Med Dis Skin*. 1869;3:117–132.
2. Carrozzo M, Thorpe R. Oral lichen planus: a review. *Minerva Stomatol*. 2009;58(10):519–537.
3. Scully C, Beyli M, Ferreiro MC, et al. Update on oral lichen planus: etiopathogenesis and management. *Crit Rev Oral Biol Med*. 1998;9(1):86–122.

4. van der Meij EH, van der Waal I. Lack of clinicopathologic correlation in the diagnosis of oral lichen planus based on the presently available diagnostic criteria and suggestions for modifications. *J Oral Pathol Med*. 2003;32(9):507–512.
5. Sugerma PB, Savage NW, Walsh LJ, et al. The pathogenesis of oral lichen planus. *Crit Rev Oral Biol Med*. 2002;13(4):350–365.
6. Pippi R, Patini R, Ghiciuc CM, Pasquantonio G, Saponaro G. Oral lichen planus and stress: evidence of altered salivary cortisol levels. *Eur Oral Investig*. 2020;24(1):47–54.
7. Warnakulasuriya S, Johnson NW, van der Waal I. Nomenclature and classification of potentially malignant disorders of the oral mucosa. *J Oral Pathol Med*. 2007;36(10):575–580.
8. Cheng YS, Gould A, Kurago Z, Fantasia J, Muller S. Diagnosis of oral lichen planus: a position paper of the American Academy of Oral and Maxillofacial Pathology. *Oral Surg Oral Med Oral Pathol Oral Radiol*. 2016;122(3):332–354.
9. Girolomoni G, Pastore S, Albanesi C, Cavani A. Psychological stress and skin-associated immune response. *Clin Dermatol*. 2003;21(1):26–29.
10. Dhabhar FS. Effects of stress on immune function: the good, the bad, and the beautiful. *Immunol Res*. 2014;58(2-3):193–210.
11. Ismail SB, Kumar SK, Zain RB. Oral lichen planus and lichenoid reactions: etiopathogenesis, diagnosis, management and malignant transformation. *J Oral Sci*. 2007;49(2):89–106.
12. Warnakulasuriya S, Tilakaratne WM. *Oral Medicine and Pathology: A Guide to Diagnosis and Management*. 1st ed. New Delhi: Jaypee Brothers Medical Publishers; 2014.
13. Krupaa RJ, Sankari SL, Masthan KM, Rajesh E. Oral lichen planus: an overview. *J Pharm Bioallied Sci*. 2015;7(Suppl 1):S158–161.
14. Eisen D. The evaluation of cutaneous, genital, scalp, nail, esophageal and ocular involvement in patients with oral lichen planus. *Oral Surg Oral Med Oral Pathol Oral Radiol Endod*. 1999;88(4):431–436.
15. Lodi G, Scully C, Carrozzo M, Griffiths M, Sugerma PB, Thongprasom K. Current controversies in oral lichen planus: report of an international consensus meeting. Part 2. Clinical management and malignant transformation. *Oral*

- Surg Oral Med Oral Pathol Oral Radiol Endod. 2005;100(2):164–178.
16. Thongprasom K, Carrozzo M, Furness S, Lodi G. Interventions for treating oral lichen planus. Cochrane Database Syst Rev. 2011;(7):CD001168.
17. Manolache L, Seceleanu-Petrescu D, Benea V. Lichen planus patients and stressful events. J Eur Acad Dermatol Venereol. 2008;22(4):437–441.