

# Epidermolysis bullosa simplex with muscular dystrophy. Review of the literature and a case report

Jana Kyrova<sup>1,2</sup>, Lenka Kopeckova<sup>3</sup>, Hana Buckova<sup>1,2</sup>, Lenka Mrazova<sup>4</sup>, Karel Vesely<sup>5</sup>, Marketa Hermanova<sup>5</sup>, Hana Oslejskova<sup>4</sup>, Lenka Fajkusova<sup>3</sup>

1. Department of Pediatric Dermatology, Pediatric Clinic, University Hospital Brno and Masaryk University Brno, Brno, Czech Republic;

2. EB Centre Czech Republic, University Hospital Brno and Masaryk University Brno, Brno, Czech Republic;

3. Centre of Molecular Biology and Gene Therapy, University Hospital Brno and Masaryk University Brno, Brno, Czech Republic;

4. Clinic of Pediatric Neurology, University Hospital and Masaryk University Brno, Brno, Czech Republic;

5. 1st Department of Pathological Anatomy, St. Anne's University Hospital Brno and Masaryk University Brno, Brno, Czech Republic.

## Corresponding author:

Jana Kyrova

Department of Pediatric Dermatology  
Pediatric Clinic

University Hospital Brno and Masaryk  
University Brno

Jihlavska 20, Brno, 62500

Czech Republic

E-mail: [jana.kyrova@email.cz](mailto:jana.kyrova@email.cz)

## Abstract

**Background:** Epidermolysis bullosa simplex associated with muscular dystrophy is a genetic skin disease caused by plectin deficiency. A case of a 19-year-old Czech patient affected with this disease and a review all previously published clinical cases are presented.

**Main observations:** In our patient, skin signs of the disease developed after birth. Bilateral ptosis at the age of 8 years was considered as the first specific symptom of muscular dystrophy. Since then, severe scoliosis, urological and psychiatric complication have quickly developed. The signs of plectin deficiency were found by histopathological studies, electron microscopy and antigen mapping of the skin and muscular samples. Two autosomal recessive mutations in the plectin gene leading to premature termination codon were disclosed by mutation analysis. By review of all published clinical cases, 49 patients with this disease were found. 54 different mutations in the plectin gene were published, p.(Arg2319\*) in exon 31 being the most frequently found. Median age of muscular dystrophy development was 9.5 years. Hoarseness and respiratory complications were the most often complications beside skin involvement.

**Conclusion:** Epidermolysis bullosa simplex with muscular dystrophy was diagnosed based on clinical, histopathological (skin and muscle biopsy) and mutation analysis of the plectin gene. Overview of the genetic and clinical characteristic of this disease could be presented by review of all previously published clinical cases. (*J Dermatol Case Rep.* 2016; 10(3): 39-48)

## Keywords:

epidermolysis bullosa, muscular dystrophy, mutation, neuromuscular disorder, plectin, review

## Introduction

Epidermolysis bullosa simplex (EBS) with muscular dystrophy (EBS-MD) is a rare life threatening subtype of basal EBS with autosomal recessive inheritance. The first cases of patients with EBS-MD were published in 1988 by Niemi, at this time the genetic bases were not known.<sup>1</sup> The affected gene was described in 1996 by a team comprising of Mc Lean and Smith.<sup>2</sup> The disease is caused by genetic defects in the plectin gene, a multi-domain protein expressed in epithelia, muscles and fibroblasts. Plectin is a member of the plakin family of proteins and plays a critical role in the formation

of hemidesmosomes and securing the interactions of intermediate filaments to the plasma membrane attachment sites.<sup>3,4</sup> We report an unusual clinical case of a patient with SEB-MD, psychiatric complications and new mutations in the PLEC1 gene. We also review the available literature regarding this disease.

We conducted a PubMed search of articles published in accessible English language journals using the terms "epidermolysis bullosa", "simplex", "dystrophy", "muscular", "plectin". Out of 64 articles found 29 articles were relevant including a review of described cases. References within these articles disclosed additional cases.

## Case report

### Case history

The proband is 19-year-old Czech boy treated in the EB Centre of the Czech Republic (Table 1, ID 49). He is the child of healthy non-consanguineous Caucasian parents without any preceding history of neurological or neuromuscular disease. He was born at term via Caesarean section. Hoarseness and skin involvement (erosions of the skin and oral mucosae, widespread blistering with hemorrhagic blisters and onychodystrophy) have been present since birth. The patient had extrasystoles during the first 3 days of life, from then arrhythmia disappeared without any consequences. A skin biopsy for histological examination (light and electron microscopy) was taken in his 4th month of life. The results confirmed that he was to be considered as junctional EB. Signs of delay of motor skills were present from the first year of age — delay in sitting (not in 14 months), creeping (never) and walking (from 2 years). The speech and cognitive development were brilliant with ability to read in 3 years of age. Skin conditions improved at the age of 2 and blistering persisted mainly on hands, feet and in the face (periorificial). The lesions healed with mild atrophy, leukodermas, hyperpigmentation and occasional milias. The patient suffered from widespread plantar keratoderma with

painful and difficult walking from infancy. Specific signs of MD have been present since 8 years of age when bilateral ptosis developed. At the beginning, muscle weakness and pain in walking were considered as consequences of feet involvement. The muscle weakness became more prominent in 11 years with a wheelchair becoming necessary for longer distances. The patient's family refused the examinations recommended (second skin biopsy for AMP, muscle biopsy and DNA molecular diagnostics) and their contact with the EB Centre was interrupted. At the age of 13 fatigue and muscle pain were more prominent. Only a few steps could be walked with support of another person, his arms could not be raised above the horizontal line and severe spine deformity developed. Neurological examination in the EB Centre was performed at the age of 14 and muscle hypotrophy, areflexia, joint contractures, bilateral ptosis and scoliosis of thoracic and lumbar spine with left-sided curve were disclosed (Fig. 1). Laboratory examinations found the serum level of myogenic enzymes was elevated (creatine kinase 14.15  $\mu\text{kat/l}$ , lactate dehydrogenase 4.05  $\mu\text{kat/l}$ ), no abnormalities were found in a periphery blood test, liver and kidney function tests. Myogenic pattern in needle electromyography was disclosed. No abnormality was found by brain MRI, cardiological and ophthalmologic examinations.

The parents finally agreed to a second skin biopsy for AMP, muscle biopsy and blood collection for DNA molecular analysis of the plectin gene.

Depression and aggression against parents was observed at the age of 15 and since then the patient has been on psychiatric medication and has been receiving psychological care. Repeated urine retentions have been present since 16 years and led to suprapubic cystostomy.

### Electron microscopy of the skin

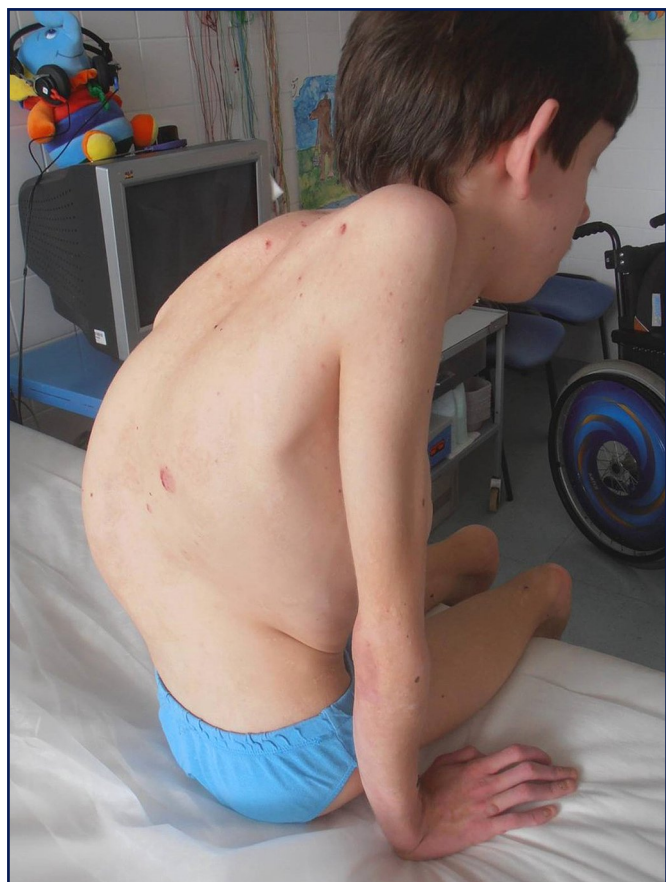A skin biopsy sample was fixed in glutaraldehyde and post-fixed in osmium tetroxide and embedded in Epon. Ultrathin sections were mounted on copper grids and contrasted with uranyl acetate and lead citrate and then examined using transmission electron microscope Tesla BS 500. Electronograms showed intraepidermal split formation with lamina densa and lucida and hemidesmosomes on the floor of the blister.

### Immunofluorescence antigen basement membrane zone mapping

Indirect immunofluorescence method was used with primary antibodies directed against plectin, cytokeratins 5 and 14, integrins  $\alpha 6$  and  $\beta 4$ , collagens type IV, VII and XVII and laminin 5. In the patient's skin sample an unaltered signal with anti-cytokeratin, anti-integrin, anti-collagen IV, VII and XVII and anti-BPAG1 was observed in comparison with control whereas no signal was detected with an anti-plectin antibody (Fig. 2).

### Muscle biopsy: light microscopy and ultrastructural examination

An opened biopsy from the quadriceps femoris was performed. Muscle tissue was snap frozen in a propane-butane



**Figure 1**

*Clinical features of the patient at the age of 19 years. Severe scoliosis of thoracic and lumbar spine with left-sided curve.*



mixture cooled in liquid nitrogen. Part of the muscle biopsy was fixed in glutaraldehyde and an ultrastructural examination was also performed. Cryosections were examined by conventional histological, histochemical, immunohistochemical and immunofluorescence methods.

Light microscopy of muscle biopsy displayed a myopathic pattern with evidence of fiber necrosis and regeneration, with significant variation in fiber size, grouped atrophic fibers and an increased amount of endomysial and perimysial connective and fatty tissue. Pyknotic nuclear clumps and multiple internal nuclei were also present (Fig. 3). Small perivascular and endomysial inflammatory infiltrates were focally observed. In summary, the muscle biopsy showed features of muscular dystrophy with inflammatory pattern. Immunohistochemistry revealed normal expressions of dystrophin, dysferlin,  $\alpha$ -dystroglycan, sarcoglycans, merosin and emerin. In the majority of muscle fibers, cytoplasmic and sarcolemmal desmin-positive deposits were demonstrated. Plectin immunofluorescence showed absence of this protein in muscle fibers. Ultrastructural changes included the increased space between sarcolemma and muscle sarcomere, areas of myofibrillar disorganization, increased amount of glycogen intermyofibrillary, a variation in normal Z-line size and lack of uniformity between sarcomeres.

### Mutation analysis for PLEC1 gene:

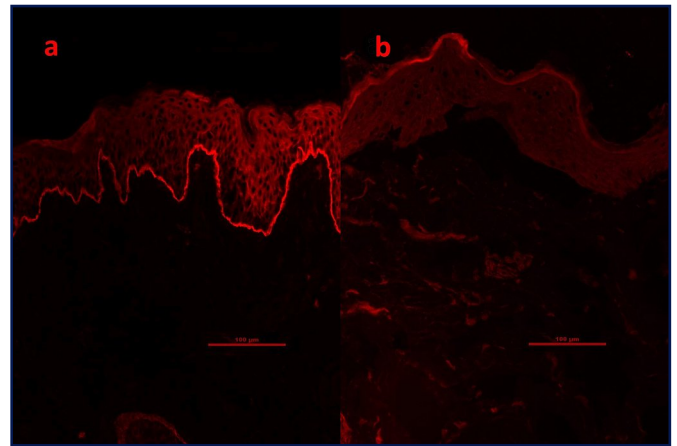
Genomic DNA was isolated from peripheral blood samples of the proband and his immediate family members. The mutation detection was performed after polymerase chain reaction (PCR) amplification of PLEC1 exons and intron-exon borders, followed by direct automated sequencing using an ABI PRISM 3130xl genetic analyzer (Applied Biosystems, Foster City, CA).

PLEC1 mutational analysis revealed that the proband was compound heterozygote for maternal mutation c.5902\_5903del and paternal mutation c.9109\_9125del. The designation of the PLEC1 (Genebank NM\_000445.4) mutations and numbering of the nucleotides and amino acids was performed according to nomenclature recommendations.<sup>5</sup> Both mutations are predicted to result from premature stop codon during protein translation, which results in truncated polypeptides and downregulation of the corresponding mRNA through nonsense-mediated mRNA decay. Both of the mutations were novel.

From the results of the above studies, EBS-MD due to plectin deficiency was diagnosed.

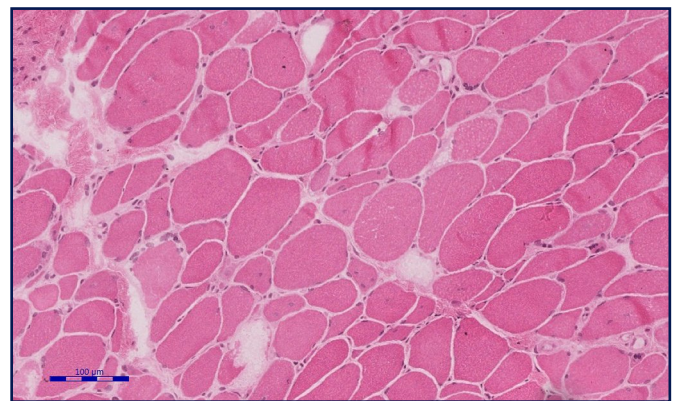
## Discussion

EBS is a group of blistering genodermatoses characterized by blister formation above the basement membrane of dermo-epidermal junction. Seventeen EBS subtypes are recognized according to the recent classification.<sup>6</sup> Most of the SEB subtypes are caused by mutation in genes of basal cell keratins (K5 and K14), but also plectin,  $\alpha$ 6 $\beta$ 4 integrin, desmoplakin, plakoglobin and plakophilin-1 genes are related to EBS.<sup>6</sup> Mutation in the plectin gene is found in EBS with muscular



**Figure 2**

*Immunofluorescence with the anti-plectin monoclonal antibody. While the normal skin yielded a strong staining to the basement membrane zone (a), no positive staining was seen in the patient skin (b).*



**Figure 3**

*Muscle biopsy – light microscopy, stained by hematoxylin and eosin. Wide variation in muscle fiber size, with both atrophic and hypertrophic fibers, atrophic fibers individually and in small groups. Increased frequency of internal nuclei, multiple pyknotic nuclear clumps present. Increased amount of endomysial and perimysial connective and fatty tissue.*

dystrophy (EBS-MD), EBS with pyloric atresia (EBS-PA), EBS Ogna (EBS-Og) and a recently described type caused by plectin isoform 1a disruption leading to autosomal-recessive skin-only EBS.<sup>6,7</sup> EBS-MD and EBS-PA are very rare life threatening diseases with autosomal recessive inheritance.

EBS-MD is a rare variant of EBS caused by mutations of the human plectin gene (PLEC1) on chromosome 8q24. Plectin is a versatile cytoskeletal linker protein with high molecular weight (530 kDa), expressed in several cell types (epithelia, muscles and fibroblasts). It comprises N and C-terminal domains, which contain multiple protein-protein interaction sites, separated by an elongated central rod domain, which is predicted to mediate self-association via coil-coil interactions.<sup>8</sup> In particular, the N-terminal region contains an actin-binding domain (ABD) and a plakin domain, which harbor binding sites for two hemidesmosomal proteins: integrin  $\alpha$ 6 $\beta$ 4 and collagen type XVII.<sup>9,10</sup> The C-terminal region

contains six plakin domains and harbors binding sites for intermediate filaments, vinculin and integrin.<sup>11</sup> Consistent with its numerous binding partners, plectin mutation results in pleiotropic phenotypes.<sup>12</sup>

The human plectin gene (PLEC1) consists of 32 exons spanning approximately 32 kb of DNA. The relatively small exons 1-30 encode the aminoterminal domain of the molecule, the central rod and the carboxyterminal domains are encoded by single exons, 31 and 32, which are exceptionally large, approximately 3 and 6 kb, respectively.<sup>13</sup>

From the analysis of published plectin mutations it is clear, that EBS-MD is usually a result of nonsense, insertion or deletion mutations of exon 31, which encodes for the second rod domain. In these patients the full-length plectin is absent, but they typically express a rodless plectin isoform, which delays the onset of MD because of the remaining IF-binding site.<sup>13,14</sup> In EBS-PA patients the more severe disease phenotype is caused by the fact that both full-length and rodless plectin isoforms are deficient.<sup>15</sup>

So far, 49 patients with EBS-MD have been described in the literature (our patient included). DNA molecular analysis of the plectin gene was performed in 43 patients (88%). Mutations on both alleles were identified in 41 patients, only one mutated allele in 2 patients. Almost half of the patients (20) were homozygotes. In summary, 54 different mutations in eight exons (9, 14, 19, 21, 22, 24, 31, 32) and in three introns (i11, i25, i30) were found by DNA molecular analysis. Mutations were mostly located in exons 31 (69% of all mutations) and 32 (14% of all mutations), see Table 1.

Most frequently, glutamine (27% of all mutations), glutamic acid (24% of all mutations) and arginine (20% of all mutations) were replaced by other amino acids. Mutation p.(Arg2319\*) in exon 31 was found most often (five times).

Two different previously unpublished mutations, p.(Lys1968Glyfs\*44) in exon 31 and p.(Val3037Cysfs\*78) in exon 32, were detected in our patient (ID 49). Both are pathogenic and lead to PTC.

Patients with EBS-MD usually do not have muscular symptoms at birth, but muscle weakness appears later in their life. The type of PLEC1 mutations (PTC-causing mutations or in-frame insertions/ deletions) influences the timing of MD onset.<sup>16</sup>

At the time of paper's publication, MD has already been present in 38 (our patient included) out of 49 patients (78%). Precise time of the MD onset has been reported in 31 patients, who have been enrolled in further analysis of MD. By the term "infant" a child between 0-2 years was understood. In 3 cases MD was stated as present without any specification and 5 patients were excluded from further analysis because of the wide range of age hidden in terms "childhood", "teens" and "adolescence", see Table 1.

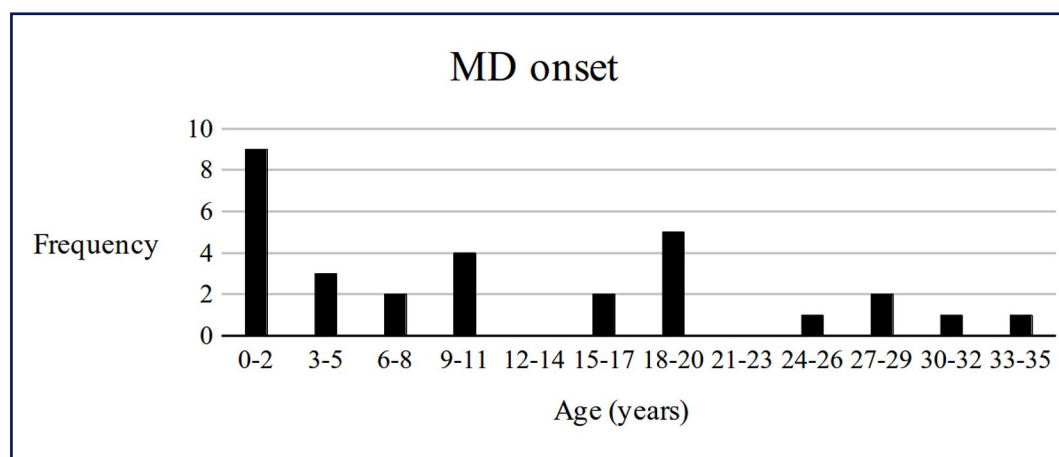
Median age at the first signs of MD was 9.5 years. Two patients presented MD at birth (ID 1, 40), the latest onset of the first signs of MD was at 35 years of age (ID 15). The main peak of MD development was during first two years of life (30%, 9 patients), 58% of cases developed by 11 years (18 patients) and 83% by 20 years (25 patients), see Fig. 4.

Until the date of publication of previous case reports, no MD was observed in 11 patients, the median age in this group was 4 years. One of them died at 4 years of age because of respiratory obstruction without symptoms of MD (ID 29), see Table 1.

In our patient, unspecific signs of MD have been present since infancy (delayed motoric development), bilateral ptosis at the age of 8 years is considered as the first specific symptom of MD.

Information about survival of patients was published in 41 cases (our patient included). Five of them have died prior to the date of case publication. One patient died at 6 months (ID 7) and another patient in 4 years (ID 29), both because of respiratory complications. Three patients died in their forties (ID 3, 4, 23), see Table 1. At the time of publication, median age of living patients was 24 years (min 5 months, max 63 years).

Skin blistering developed at birth or soon after birth in almost all patients (47 patients). In the remaining two cases skin blistering started during childhood (ID 15, 40). Skin blistering was stated as widespread in 36 patients (74% of all patients). Consequences of skin healing were described in 33 cases. Out of them, visible sequelae of blister healing were present in 18 patients, skin atrophy being the most frequently described (12 patients), followed by scarring (9 patients), milia (3 patients) and dyspigmentation (3 patients).



**Figure 4**  
Onset of MD.

The quality of nails was described in 44 patients, onychodystrophy being the most common finding (39 patients) and nail loss being described in one patient (ID 7).

Oral mucosa was noticed in 38 patients, oral mucosa involvement was present in half of the patients (20 patients), involvement was stated as severe in 3 patients (ID 2, 5, 20).

In this patient, widespread blistering was observed in infancy and improved by the age of 2 years. Since then it has persisted mainly on the hands and face, blisters heal with mild atrophy, hypopigmentation and milia. Oral lesions were observed too.

In 36 patients (74% of all patients) organ involvement beside skin was present (our patient included). Hoarseness (12 patients) and respiratory complications (12 patients) were the most frequently found. Patients suffered also from

dental involvement (9 patients), plantar keratoderma (8 patients), gastrointestinal (7 patients), neurological apart from MD (6 patients), severe urogenital (6 patients) and cardiac complications (4 patients). Signs of other diseases were less frequently found, see Table 1.

In our patient, hoarseness, short period of arrhythmia, plantar keratoderma, severe scoliosis, aggressiveness, depression and chronic urological complications were present.

## Conclusions

This case report highlight the importance of new diagnostic methods in diagnostics of EB. By review of all reported cases, variability of symptoms of EBS-MD could be demonstrated.

**Table 1:** Overview of EBS-MD cases.

ID / Reference	1. Mutation – nucleotide	Protein	Exon	2. Mutation – nucleotide	Protein	Exon	MD (year of onset)	Died (age)	Other symptoms
1 <sup>17</sup>	c.1530_1531 ins36	p.(Ala510_Ile511ins12)	14	c.1530_1531 ins36	p.(Ala510_Ile511ins12)	14	Y (birth)	N (63y)	alopecia totalis, congenital myasthenic syndrome
2 <sup>18</sup>	c.5137C>T	p.(Gln1713*)	31	c.7051C>T	p.(Arg2351*)	31	N (4y)	N (4y)	hoarseness, dilatation of larynx, gastroesophageal reflux disease
3 <sup>19</sup>	c.5410G>T	p.(Glu1804*)	31	c.5410G>T	p.(Glu1804*)	31	Y (17y)	Y (44y)	hoarseness, dental abnormalities
4 <sup>19</sup>	c.5410G>T	p.(Glu1804*)	31	c.5410G>T	p.(Glu1804*)	31	Y (15y)	Y (47y)	loose of all teeth, partial deafness
5 <sup>20</sup>	c.5257dup	p.(Glu1753 Glyfs*17)	31	c.5257dup	p.(Glu1753 Glyfs*17)	31	N (3y)	N (3y)	tracheostomy
6 <sup>21</sup>	c.968G>A	p.(Arg323Gln)	9	c.4840G>T	p.(Glu1614*)	31	Y (20y)	N (40y)	dilated cardiomyopathy
7 <sup>22</sup>	not performed			not performed			Y (0.1y)	Y (0.5y)	hoarseness, intubation, blood transfusions
8 <sup>22</sup>	not performed			not performed			Y		
9 <sup>22</sup>	not performed			not performed			Y		alopecia
10 <sup>22</sup>	not performed			not performed			Y		
11 <sup>23</sup>	c.13459_13474 dup	p.(Glu4492 Glyfs*48)	32	c.13459_13474dup	p.(Glu4492 Glyfs*48)	32	Y (11y)	N (25y)	left ventricular hypertrophy, brain atrophy, delayed motor development (walking in 4 y), bilateral cataract
12 <sup>9/24</sup>	c.5806C>T	p.(Gln1936*)	31	c.3157C>T	p.(Gln1053*)	24	Y (infancy)	N (9y)	dental involvement, urethral stricture

ID / Reference	1. Mutation – nucleotide	Protein	Exon	2. Mutation – nucleotide	Protein	Exon	MD (year of onset)	Died (age)	Other symptoms
13 <sup>9/24</sup>	c.7261C>T	p.(Arg2421*)	31	c.12578_12581dup	p.(Tyr4195Aspfs*41)	32	Y (5y)	N (33y)	scarring alopecia
14 <sup>24/25</sup>	c.5815del	p.(Leu1939Trpfs*6)	31	c.5815del	p.(Leu1939Trpfs*6)	31	Y (20y)	N (38y)	dental involvement, urethral stricture
15 <sup>24/25</sup>	c.2677_2685del	p.(Gln893_Ala895del)	21	c.2677_2685del	p.(Gln893_Ala895del)	21	Y (35y)	N (46y)	
16 <sup>14</sup>	c.6549_6582del	p.(Leu2184Argfs*21)	31	c.13040dup	p.(Ile4348Hisfs*8)	32	Y (10y)	N (24y)	
17 <sup>14</sup>	c.4643_4667dup	p.(Lys1558Glyfs*89)	31	c.7120C>T	p.(Gln2374*)	31	N (7y)	N (7y)	hoarseness
18 <sup>11</sup>	c.4261C>T	p.(Gln1421*)	31	c.4261C>T	p.(Gln1421*)	31	Y (teens)	N (28y)	dental involvement
19 <sup>11</sup>	c.10456C>T	p.(Gln3486*)	32	c.6682C>T	p.(Gln2228*)	31	Y (5y)	N (6y)	hoarseness, severe esophageal involvement, enteral nutrition
20 <sup>11</sup>	c.6955C>T	p.(Arg2319*)	31	c.3341+1G>T		i25	N (1.5y)	N (1.5y)	hoarseness, tracheostomy, bladder hematomas, bilateral hydronephrosis, urethral stricture, anal prolapse
21 <sup>11</sup>	not found		NF	c.5770C>T	p.(Gln1924*)	31	Y (30y)	N (31y)	palmoplantar keratoderma
22 <sup>11</sup>	c.7804C>T	p.(Gln2602*)	32	c.4126-4A>G		i30	Y (18y)	N (27y)	
23 <sup>26</sup>	c.6955C>T	p.(Arg2319*)	31	c.12043dup	p.(Glu4015Glyfs*69)	32	Y (3y)	Y (42y)	respirator, gastrostomy
24 <sup>26/27</sup>	c.6169C>T	p.(Gln2057*)	31	c.12043dup	p.(Glu4015Glyfs*69)	32	Y (9y)	N (20y)	dysphagia, dyspnea, hoarseness, anemia, myasthenic syndrome
25 <sup>28/29</sup>	c.5728C>T	p.(Gln1910*)	31	c.5728C>T	p.(Gln1910*)	31	Y (infancy)	N (29y)	palmoplantar keratoderma
26 <sup>28/29</sup>	not performed			not performed			Y (infancy)	N (27y)	palmoplantar keratoderma
27 <sup>30</sup>	c.4348C>T	p.(Gln1450*)	31	c.4348C>T	p.(Gln1450*)	31	Y (19y)	N (49y)	dental involvement, immobility, respirator
28 <sup>31</sup>	c.5018_5036del	p.(Leu1673Argfs*64)	31	c.5018_5036del	p.(Leu1673Argfs*64)	31	N (5.5y)	N (5.5y)	hoarseness, palmoplantar keratoderma
29 <sup>31</sup>	c.5855_5856del	p.(Glu1952Glyfs*60)	31	c.5855_5856del	p.(Glu1952Glyfs*60)	31	N (4y)	Y (4y)	hoarseness, tracheostomy, plantar keratoderma



ID / Reference	1. Mutation – nucleotide	Protein	Exon	2. Mutation – nucleotide	Protein	Exon	MD (year of onset)	Died (age)	Other symptoms
30 <sup>10</sup>	c.6955C>T	p.(Arg2319*)	31	c.6955C>T	p.(Arg2319*)	31	Y (25y)	N (52y)	dental abnormalities
31 <sup>8</sup>	c.6013G>T	p.(Glu2005*)	31	c.13378A>T	p.(Lys4460*)	32	N (0.5y)	N (0.5y)	
32 <sup>8</sup>	c.5032del	p.(Val1678 Trpfs*65)	31	c.2694-9_2705del		22	N (0.4y)	N (0.4y)	
33 <sup>32</sup>	c.4222C>T	p.(Gln1408*)	31	c.954_956dup	p.(Leu319dup)	9	N (4y)	N (4y)	
34 <sup>33</sup>	c.4365del	p.(Ser1456 Argfs*93)	31	c.4294_4306dup	p.(Val1436Glyfs*40)	31	Y (20y)		dental abnormalities, laryngeal webs, urethral stricture
35 <sup>2</sup>	c.5105_5112del	p.(Arg1702 Glnfs*14)	31	c.5105_5112del	p.(Arg1702 Glnfs*14)	31	Y (10y)	N (24y)	dental abnormalities
36 <sup>3</sup>	c.7393C>T	p.(Arg2465*)	31	c.7393C>T	p.(Arg2465*)	31	Y (teens)		
37 <sup>3</sup>	c.5257dup	p.(Glu1753 Glyfs*17)	31	c.5257dup	p.(Glu1753 Glyfs*17)	31	Y (1.1y)		
38 <sup>3</sup>	c.4840G>T	p.(Glu1614*)	31	c.4840G>T	p.(Glu1614*)	31	Y (teens)		
39 <sup>3</sup>	c.7261C>T	p.(Arg2421*)	31	pending			Y (childhood)		
40 <sup>34</sup>	c.10187_10190del	p.(Val3396 Alafs*11)	32	c.1250+2T>G		i11	Y (birth)	N (8y)	mild respiratory distress
41 <sup>35</sup>	not performed			not performed			N (3y)	N (3y)	tracheal and bronchial stenosis, tracheostomy, gastrostomy
42 <sup>36</sup>	c.4930C>T	p.(Gln1644*)	31	c.2677_2685del	p.(Gln893_Ala895del)	21	Y (28y)	N (42y)	
43 <sup>37</sup>	c.7393C>T	p.(Arg2465*)	31	c.7393C>T	p.(Arg2465*)	31	Y (2y)	N (38y)	brain atrophy
44 <sup>37</sup>	c.5855_5856del	p.(Glu1952 Glyfs*60)	31	c.5855_5856del	p.(Glu1952 Glyfs*60)	31	N (10y)	N (10y)	hoarseness, tracheostomy
45 <sup>38</sup>	c.7051C>T	p.(Arg2351*)	31	c.7051C>T	p.(Arg2351*)	31	Y (2y)	N (18y)	strabismus, meatal stenosis, dysphagia, mild intellectual disability, plantar keratoderma, left ventricular non-compaction
46 <sup>39</sup>	c.4924C>T	p.(Gln1642*)	31	c.6955C>T	p.(Arg2319*)	31	Y (adolescence)	N (25y)	non-scarring alopecia, albopapuloid lesions

ID / Reference	1. Mutation – nucleotide	Protein	Exon	2. Mutation – nucleotide	Protein	Exon	MD (year of onset)	Died (age)	Other symptoms
47 <sup>40</sup>	c.6292C>T	p.(Gln2098*)	31	c.7789C>T	p.(Gln2597*)	32	Y (6y)	N (14y)	hoarseness, congenital scoliosis, focal plantar keratoderma
48 <sup>41</sup>	c.2264_2266del	p.(Phe755del)	19	c.3119_3120del	p.(Lys1040Argfs*139)	24	Y (27y)	N (35y)	dizziness, unconsciousness, dilated cardiomyopathy, arrhythmia
49	c.5902_5903del	p.(Lys1968 Glyfs*44)	31	c.9109_9125del	p.(Val3037Cysfs*78)	32	Y (8y)	N (19y)	arrhythmia, severe scoliosis, hoarseness, aggressiveness, depression, plantar keratoderma, suprapubic cystostomy

N: No, Y: yes, y: years

## References

- Niemi KM, Sommer H, Kero M, Kanerva L, Haltia M. Epidermolysis bullosa simplex associated with muscular dystrophy with recessive inheritance. *Arch Dermatol.* 1988; 124: 551-554. PMID: 3355199.
- McLean WH, Pulkkinen L, Smith FJ, Rugg EL, Lane EB, Bullrich F, Burgeson RE, Amano S, Hudson DL, Owaribe K, McGrath JA, McMillan JR, Eady RA, Leigh IM, Christiano AM, Uitto J. Loss of plectin causes epidermolysis bullosa with muscular dystrophy: cDNA cloning and genomic organization. *Genes Dev.* 1996; 10: 1724-1735. PMID: 8698233.
- Pfendner E, Rouan F, Uitto J. Progress in epidermolysis bullosa: the phenotypic spectrum of plectin mutations. *Exp Dermatol.* 2005; 14: 241-249. PMID: 15810881.
- Borradori L, Sonnenberg A. Structure and function of hemidesmosomes: more than simple adhesion complexes. *J Invest Dermatol.* 1999; 112: 411-418. PMID: 10201522.
- Reznicek GA, Walko G, Wiche G. Plectin gene defects lead to various forms of epidermolysis bullosa simplex. *Dermatol Clin.* 2010; 28: 33-41. PMID: 19945614.
- Fine JD, Bruckner-Tuderman L, Eady RA, Bauer EA, Bauer JW, Has C, Heagerty A, Hintner H, Hovnanian A, Jonkman MF, Leigh I, Marinkovich MP, Martinez AE, McGrath JA, Mellerio JE, Moss C, Murrell DF, Shimizu H, Uitto J, Woodley D, Zamburino G. Inherited epidermolysis bullosa: updated recommendations on diagnosis and classification. *J Am Acad Dermatol.* 2014; 70: 1103-1126. PMID: 24690439.
- Gostyrńska KB, Nijenhuis M, Lemmink H, Pas HH, Pasmooij AM, Lang KK, Castañón MJ, Wiche G, Jonkman MF. Mutation in exon 1a of PLEC, leading to disruption of plectin isoform 1a, causes autosomal-recessive skin-only epidermolysis bullosa simplex. *Hum Mol Genet.* 2015; 24: 3155-3162. PMID: 25712130.
- Rouan F, Pulkkinen L, Meneguzzi G, Laforgia S, Hyde P, Kim DU, Richard G, Uitto J. Epidermolysis bullosa: novel and de novo premature termination codon and deletion mutations in the plectin gene predict late-onset muscular dystrophy. *J Invest Dermatol.* 2000; 114: 381-387. PMID: 10652002.
- Takizawa Y, Shimizu H, Rouan F, Kawai M, Udonon M, Pulkkinen L, Nishikawa T, Uitto J. Four novel plectin gene mutations in Japanese patients with epidermolysis bullosa with muscular dystrophy disclosed by heteroduplex scanning and protein truncation tests. *J Invest Dermatol.* 1999; 112: 109-112. PMID: 9886273.
- Takahashi Y, Rouan F, Uitto J, Ishida-Yamamoto A, Iizuka H, Owaribe K, Tanigawa M, Ishii N, Yasumoto S, Hashimoto T. Plectin deficient epidermolysis bullosa simplex with 27-year-history of muscular dystrophy. *J Dermatol Sci.* 2005; 37: 87-93. PMID: 15659326.
- Charlesworth A, Chiaverini C, Chevrant-Breton J, DelRio M, Diociaiuti A, Dupuis RP, El Hachem M, Le Fiblec B, Sankari-Ho AM, Valhquist A, Wierzbicka E, Lacour JP, Meneguzzi G. Epidermolysis bullosa simplex with PLEC mutations: new phenotypes and new mutations. *Br J Dermatol.* 2013; 168: 808-814. PMID: 23289980.
- Wiche G. Role of plectin in cytoskeleton organization and dynamics. *J Cell Sci.* 1998; 111: 2477-2486. PMID: 9701547.



13. Koster J, van Wilpe S, Kuikman I, Litjens SH, Sonnenberg A. Role of binding of plectin to the integrin beta4 subunit in the assembly of hemidesmosomes. *Mol Biol Cell*. 2004; 15: 1211-1223. PMID: 14668477.
14. Natsuga K, Nishie W, Akiyama M, Nakamura H, Shinkuma S, McMillan JR, Nagasaki A, Has C, Ouchi T, Ishiko A, Hirako Y, Owaribe K, Sawamura D, Bruckner-Tuderman L, Shimizu H. Plectin expression patterns determine two distinct subtypes of epidermolysis bullosa simplex. *Hum Mutat*. 2010; 31: 308-316. PMID: 20052759.
15. Natsuga K, Nishie W, Shinkuma S, Arita K, Nakamura H, Ohyama M, Osaka H, Kambara T, Hirako Y, Shimizu H. Plectin deficiency leads to both muscular dystrophy and pyloric atresia in epidermolysis bullosa simplex. *Hum Mutat*. 2010; 31: E1687-1698. PMID: 20665883.
16. Chiavérini C, Charlesworth A, Meneguzzi G, Lacour JP, Ortonne JP. Epidermolysis bullosa simplex with muscular dystrophy. *Dermatol Clin*. 2010; 28: 245-255. PMID: 20447487.
17. Maselli RA, Arredondo J, Cagney O, Mozaffar T, Skinner S, Yousif S, Davis RR, Gregg JP, Sivak M, Konia TH, Thomas K, Wollmann RL. Congenital myasthenic syndrome associated with epidermolysis bullosa caused by homozygous mutations in PLEC1 and CHRNE. *Clin Genet*. 2011; 80: 444-451. PMID: 21175599.
18. Kunz M, Rouan F, Pulkkinen L, Hamm H, Jeschke R, Bruckner-Tuderman L, Bröcker EB, Wiche G, Uitto J, Zillikens D. Mutation reports: epidermolysis bullosa simplex associated with severe mucous membrane involvement and novel mutations in the plectin gene. *J Invest Dermatol*. 2000; 114: 376-380. PMID: 10652001.
19. Koss-Harnes D, Høyheim B, Jonkman MF, de Groot WP, de Weertd CJ, Nikolic B, Wiche G, Gedde-Dahl T Jr. Life-long course and molecular characterization of the original Dutch family with epidermolysis bullosa simplex with muscular dystrophy due to a homozygous novel plectin point mutation. *Acta Derm Venereol*. 2004; 84: 124-131. PMID: 15206692.
20. Schara U, Tücke J, Mortier W, Nüsslein T, Rouan F, Pfendner E, Zillikens D, Bruckner-Tuderman L, Uitto J, Wiche G, Schröder R. Severe mucous membrane involvement in epidermolysis bullosa simplex with muscular dystrophy due to a novel plectin gene mutation. *Eur J Pediatr*. 2004; 163: 218-222. PMID: 14963703.
21. Bolling MC, Pas HH, de Visser M, Aronica E, Pfendner EG, van den Berg MP, Diercks GF, Suurmeijer AJ, Jonkman MF. PLEC1 mutations underlie adult-onset dilated cardiomyopathy in epidermolysis bullosa simplex with muscular dystrophy. *J Invest Dermatol*. 2010; 130: 1178-1181. PMID: 20016501.
22. Patrizi A, Di Lernia V, Neri I, Badiali De Giorgi L, Masi M. Epidermolysis bullosa simplex associated with muscular dystrophy: A new case. *Pediatr Dermatol*. 1994; 11: 342-345. PMID: 7899187.
23. Schröder R, Kunz WS, Rouan F, Pfendner E, Tolksdorf K, Kappes-Horn K, Altenschmidt-Mehring M, Knoblich R, van der Ven PF, Reimann J, Fürst DO, Blümcke I, Vielhaber S, Zillikens D, Eming S, Klockgether T, Uitto J, Wiche G, Rolfs A. Disorganization of the desmin cytoskeleton and mitochondrial dysfunction in plectin-related epidermolysis bullosa simplex with muscular dystrophy. *J Neuropathol Exp Neurol*. 2002; 61: 520-530. PMID: 12071635.
24. Shimizu H, Takizawa Y, Pulkkinen L, Murata S, Kawai M, Hachisuka H, Udonon M, Uitto J, Nishikawa T. Epidermolysis bullosa simplex associated with muscular dystrophy: phenotype-genotype correlations and review of the literature. *J Am Acad Dermatol*. 1999; 41: 950-956. PMID: 10570379.
25. Pulkkinen L, Smith FJ, Shimizu H, Murata S, Yaoita H, Hachisuka H, Nishikawa T, McLean WH, Uitto J. Homozygous deletion mutations in the plectin gene (PLEC1) in patients with epidermolysis bullosa simplex associated with late-onset muscular dystrophy. *Hum Mol Genet*. 1996; 5: 1539-1546. PMID: 8894687.
26. Selcen D, Juel VC, Hobson-Webb LD, Smith EC, Stickler DE, Bite AV, Ohno K, Engel AG. Myasthenic syndrome caused by plectinopathy. *Neurology*. 2011; 76: 327-336. PMID: 21263134.
27. Banwell BL, Russel J, Fukudome T, Shen XM, Stilling G, Engel AG. Myopathy, myasthenic syndrome, and epidermolysis bullosa simplex due to plectin deficiency. *J Neuropathol Exp Neurol*. 1999; 58: 832-846. PMID: 10446808.
28. Gache Y, Chavanas S, Lacour JP, Wiche G, Owaribe K, Meneguzzi G, Ortonne JP. Defective expression of plectin in epidermolysis bullosa simplex with muscular dystrophy. *J Clin Invest*. 1996; 97: 2289-2298. PMID: 8636409.
29. Chavanas S, Pulkkinen L, Gache Y, Smith FJ, McLean WH, Uitto J, Ortonne JP, Meneguzzi G. A homozygous nonsense mutation in the PLEC1 gene in patients with Epidermolysis bullosa simplex with muscular dystrophy. *J Clin Invest*. 1996; 98: 2196-2200. PMID: 8941634.
30. Sawamura D, Goto M, Sakai K, Nakamura H, McMillan JR, Akiyama M, Shirado O, Oyama N, Satoh M, Kaneko F, Takahashi T, Konno H, Shimizu H. Possible involvement of exon 31 alternative splicing in phenotype and severity of epidermolysis bullosa caused by mutation in PLEC1. *J Invest Dermatol*. 2007; 127: 1537-1540. PMID: 17273164.
31. Mellerio JE, Smith FJ, McMillan JR, McLean WH, McGrath JA, Morrison GA, Tierney P, Albert DM, Wiche G, Leigh IM, Geddes JF, Lane EB, Uitto J, Eady RA. Recessive epidermolysis bullosa simplex associated with plectin mutations: infantile respiratory complications in two unrelated cases. *Br J Dermatol*. 1997; 137: 898-906. PMID: 9470905.
32. Bauer JW, Rouan F, Kofler B, Reznicek GA, Kornacker I, Muss W, Hametner R, Klaussegger A, Huber A, Pohla-Gubo G, Wiche G, Uitto J, Hintner H. A compound heterozygous one amino-acid insertion/nonsense mutation in the plectin gene causes epidermolysis bullosa simplex with plectin deficiency. *Am J Pathol*. 2001; 158: 617-625. PMID: 11159198.
33. Dang M, Pulkkinen L, Smith FJ, McLean WH, Uitto J. Novel compound heterozygous mutations in the plectin gene in epidermolysis bullosa with muscular dystrophy and the use of protein truncation test for detection of premature termination codon mutations. *Lab Invest*. 1998; 78: 195-204. PMID: 9484717.
34. Forrest K, Mellerio JE, Robb S, Dopping-Hepenstal PJ, McGrath JA, Liu L, Buk SJ, Al-Sarraj S, Wraige E, Jungbluth H. Congenital muscular dystrophy, myasthenic symptoms and epidermolysis bullosa simplex (EBS) associated with mutations in the PLEC1 gene encoding plectin. *Neuromuscul Disord*. 2010; 20: 709-711. PMID: 20624679.
35. Babić I, Karaman-Ilić M, Pustisek N, Susić S, Skarić I, Kljenak A, Cikojević D. Respiratory tract involvement in a child with epidermolysis bullosa simplex with plectin deficiency: a case report. *Int J Pediatr Otorhinolaryngol*. 2010; 74: 302-305. PMID: 20044146.

36. Yiu EM, Klaussegger A, Waddell LB, Graser N, Lloyd L, Tran K, North KN, Bauer JW, McKelvie P, Chow CW, Ryan MM, Murrell DF. Epidermolysis bullosa with late-onset muscular dystrophy and plectin deficiency. *Muscle Nerve*. 2011; 44: 135-141. PMID: 21674528.
37. McMillan JR, Akiyama M, Rouan F, Mellerio JE, Lane EB, Leigh IM, Owaribe K, Wiche G, Fujii N, Uitto J, Eady RA, Shimizu H. Plectin defects in epidermolysis bullosa simplex with muscular dystrophy. *Muscle Nerve*. 2007; 35: 24-35. PMID: 16967486.
38. Villa CR, Ryan TD, Collins JJ, Taylor MD, Lucky AW, Jefferies JL. Left ventricular non-compaction cardiomyopathy associated with epidermolysis bullosa simplex with muscular dystrophy and PLEC1 mutation. *Neuromuscul Disord*. 2015; 25: 165-168. PMID: 25454730.
39. Yin J, Ren Y, Lin Z, Wang H, Zhou Y, Yang Y. Compound heterozygous PLEC mutations in a patient of consanguineous parentage with epidermolysis bullosa simplex with muscular dystrophy and diffuse alopecia. *Int J Dermatol*. 2015; 54: 185-187. PMID: 25209331.
40. Chen Q, Lin ZM, Wang HJ, Zhang J, Yin JH, Yang Y. New mutations in the PLEC gene in a Chinese patient with epidermolysis bullosa simplex with muscular dystrophy. *Clin Exp Dermatol*. 2013; 38: 792-794. PMID: 23496806.
41. Winter L, Türk M, Harter PN, Mittelbronn M, Kornblum C, Norwood F, Jungbluth H, Thiel CT, Schlötzer-Schrehardt U, Schröder R. Downstream effects of plectin mutations in epidermolysis bullosa simplex with muscular dystrophy. *Acta Neuropathol Commun*. 2016; 4: 44. PMID: 27121971.