

An unusual presentation of giant pilomatrixoma in an adult patient

Mariam Patrícia Auada Souto¹, Marcus de Medeiros Matsushita², Graziela de Macedo Matsushita², Luís Ricardo Martinhão Souto³

1. Department of Clinical Medicine, School of Medical Sciences, Universidade de Marília (UNIMAR), Marília, São Paulo state, Brazil;
2. Department of Anatomic Pathology, School of Medical Sciences, Universidade de Marília (UNIMAR), Marília, São Paulo state, Brazil;
3. Department of Surgery, School of Medical Sciences, Universidade de Marília (UNIMAR), Marília, São Paulo state, Brazil.

Corresponding author:

Luís Ricardo Martinhão Souto

Av. Rio Branco, 1132 – Cj. 41
– Alto Cafézal

Marília-SP – Brazil – CEP:
17502-000

E-mail: lrmssouto@yahoo.com.br

Key words:

adnexal tumor, hair follicle,
pilomatricoma, pilomatrixoma,
sebaceous gland, tumor

Abstract

Background: Pilomatrixoma (OMIM ID #132600) is a benign cutaneous tumor originating from the pilosebaceous follicle and characterized by the presence of subcutaneous nodules of up to 3.0 cm in diameter, usually on the head, neck and upper extremities. It is most common in the first two decades of life and after the age of 60.

Main observations: An adult female patient was evaluated, presenting a solid tumoral lesion with erythematous surface and purplish tone, with approximately 7.5 x 5.0 cm in size, in the interscapulovertebral region. It was thought to be an epidermoid cyst, sarcoma, calcified hemangioma, giant dermatofibroma, or nodular basal cell carcinoma. The resection of the lesion was carried out and, at the histological examination, specific details were observed that led to the diagnosis of pilomatrixoma.

Conclusion: Pilomatrixoma should be suspected in the differential diagnosis of giant adnexal tumors. (*J Dermatol Case Rep.* 2013; 7(2): 56-59)

Introduction

Pilomatrixoma (PM; OMIM ID #132600) was first described in 1880 by Malherbe and Chenatais as a "calcified epithelioma of Malherbe" originated from sebaceous glands. In 1961, Forbis and Helwig demonstrated that the tumor originated from the hair matrix; therefore, the name pilomatrixoma.¹⁻³ PM is the most common hair-follicle tumor and it accounts for one of every 500 specimens submitted by dermatologists.⁴ Clinically, the lesion is a benign cutaneous tumor usually characterized by a solitary asymptomatic, firm, and skin-colored faint blue/red nodule in the deep dermis and subcutaneous tissue, with an average size of 0.5 to 3.0 cm. The lesions larger than 5.0 cm are defined as giant pilomatrixomas. Pain and tenderness may be associated symptoms.^{3,5}

The tumor is generally observed on the head, neck and upper extremities.⁶ It is a common skin neoplasm in the pediatric population, but it may be found in all age groups with bimodal peaks under the age of 30 and in the sixth/seventh

decades of life.^{5,6} Uncommon clinical-pathological variants of PM have been reported, such as bullous like, anetodermic, exophytic, perforating/ulcerated and lymphagiectatic. Multiple and familial cases have been described in association with myotonic dystrophy, Turner's syndrome, Gardner's syndrome, xeroderma pigmentosum, basal cell nevus syndrome and Sotos syndrome.^{6,7} The present paper reports an unusual and uncommon case of pilomatrixoma on the back of an adult female patient.

Case Report

A 54-year-old female patient sought the medical specialties outpatient service at School of Medical Sciences at Universidade de Marília (UNIMAR) complaining about a back injury three years ago, with progressive growth and sporadic local pain. The patient had undergone a surgery for the removal of the lesion in another hospital two and a half years before, but there was local recurrence 3 months after surgery.

The patient had hypertension, no previous skin disease or similar cases in the family.

The physical examination revealed a solid tumoral lesion of about 7.5 x 5.0 cm in size in the interscapulovertebral region on the left, adhered to deep planes and painful on palpation. The skin over the tumor was erythematous with violet hyperchromia. There was no ulceration on the surface or in the center of the tumor; it was noted a linear lesion with a cicatricial aspect, probably due to the previous surgery reported by the patient (Fig. 1). The clinical evaluation and the pre-operative laboratory tests showed no alterations. The patient underwent resection of the lesion with safety margins of 1.0 cm, under endovenous sedation and local anesthesia, with release of the edges of the surgical incision and advancement of lateral cutaneous flaps for closing the surgical incision.

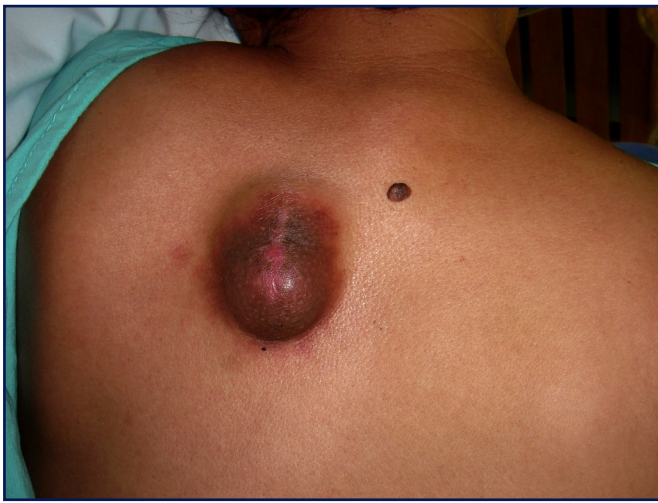

Figure 1

54-year-old female patient presenting a solid tumoral lesion with approximately 7.5 x 5.0 cm in size in the interscapulovertebral region. Erythematous skin over the tumor with violet hyperchromia and absence of surface ulcerations. It is observed a linear lesion with cicatricial aspect in the central area of the tumor.

A granular grayish raised lesion was observed at the anatomopathological examination. In the histological cuts it was observed an expansive proliferation of epithelial cell islets irregularly configured, that presented distinct limits and a stained central area that showed a shadow of lost nuclei (ghost cells). These areas sometimes were centered by keratinization. The examination also showed extensive calcium deposits and multinucleated giant cells similar to foreign bodies (Fig. 2 and 3). Therefore, based on the histopathologic features, the diagnosis of pilomatrixoma was made.

Discussion

In the case described here, the most relevant findings were the unusual size (7.5 x 5.0 cm) and the location of the skin lesion. Generally, pilomatrixomas are nodules with a diameter of 0.5 x 3.0 cm.⁸ The term "giant" refers to lesions larger

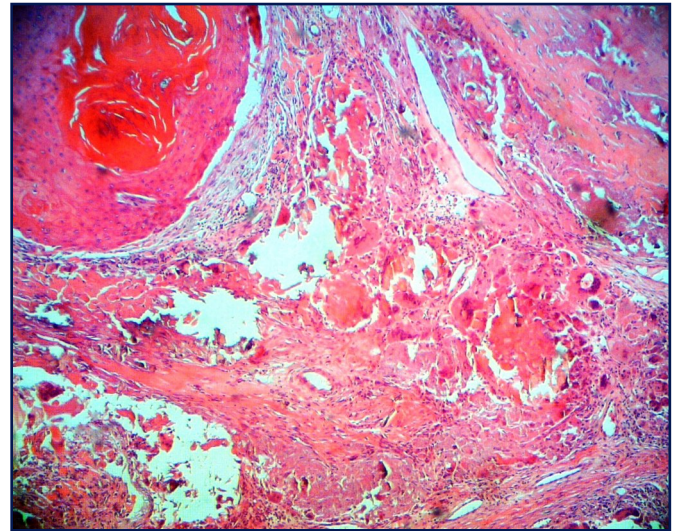


Figure 2

The figure shows an eosinophilic round center of keratinization surrounded by ghost cells. In other areas, it is observed foci of calcification and multinucleated giant cells (Hematoxylin-eosin staining, original magnification x40).

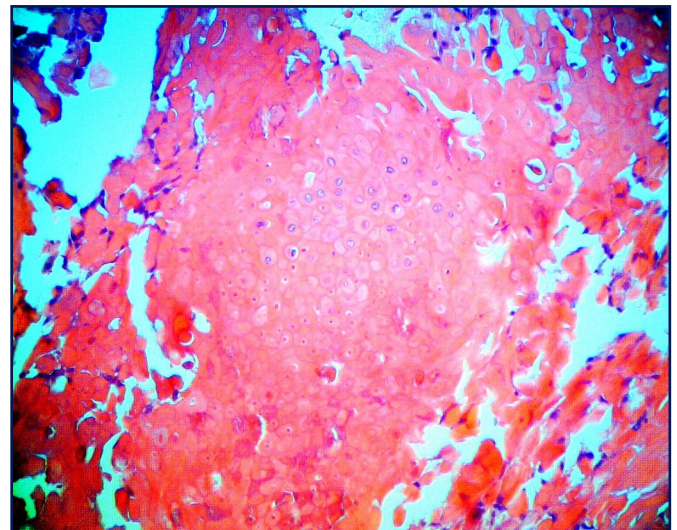


Figure 3

Cells with shadows of lost nuclei and clear intercellular limits ("ghost cells"). In this case, remaining basophilic cells are not observed, a typical finding in old lesions. (Hematoxylin-eosin staining, original magnification x100).

than 5.0 cm. Since 1974, when Krausen et al.⁹ described the first case of giant PM (GPM), few similar lesions were described⁵ and most of them were reported in male patients during the second and sixth decades of life, mainly located on the head, neck, and upper extremities, being very rare on the back.⁵ Zamanian et al.¹⁰ reported 45 cases of PM and the tumors ranged in size from 0.5 to 3.5 cm; in only five cases the tumors were larger than 2.0 cm. In the literature there are few reports of GPM in the dorsal trunk location in female patients.¹¹

Due to the variety of clinical presentations, the clinical diagnosis of GPM is difficult and PM is often clinically misdiagnosed. Previous studies indicate that the diagnostic accuracy rate in the preoperative diagnosis of PM ranges from 0 to 30%.⁴ In general, patients present a solitary nodule growing slowly over several months or years. There may be episodes of inflammation or ulceration.¹⁰

Particularly in this case, the clinical picture of pilomatrixoma made the diagnosis difficult or even impossible. It was considered the differential diagnoses of epidermoid cyst, sarcoma, calcified hemangioma, giant dermatofibroma, cutaneous lymphoma, cutaneous metastasis and basal cell carcinoma.¹² Often, imaging studies are used to assist in the diagnosis, such as computerized tomography, in which GPM appears as well-defined calcified masses separated from the subcutaneous cellular tissue by a layer of fat. Fine-needle aspiration biopsy is helpful in the diagnosis; however, the nuclear atypia seen in squamous cells and the misinterpretation of basaloid cells as malignant made the following diagnostic confusion: PM as squamous cell carcinoma, basal cell carcinoma, pleomorphic adenoma with squamous metaplasia, cutaneous and metastatic neuroendocrine carcinoma, salivary gland tumors and other tumors of skin appendages.¹³⁻¹⁵ This leads to the conclusion that at the time of aspiration, a definitive diagnosis is given only if all the major components of pilomatrixoma are present in an aspirate.¹⁶ However, if one component predominates, this may lead to an erroneous diagnosis of other benign and malignant lesions and the final diagnosis is made by histopathologic analysis.⁵

The histopathology of PM shows a well-circumscribed, deep dermal or dermal-subcutaneous tumor formed by basaloid cells that gradually lose their nuclei and mingle with the eosinophilic shadow cells that show the ghosts of epithelial cells without viable colors. The basophilic cells typically observed in this type of lesion were not evident in this case, which indicates an old lesion. The examination also showed extensive calcium deposits and multinucleated giant cells foreign-body type.³ Kaddu *et al.*¹⁷ reported that the early PM fully developed can be distinguished by histopathologic analysis, demonstrating that there is a chronological evolution of the PM lesion from an infundibular matrix cyst to a calcified and ossified dermal nodule.

A typical fully developed pilomatrixoma is a cystic lesion composed by cornified material and shadow cells surrounded by foci of basaloid cells aligned at the periphery. Malignant transformation is rarely seen in PM. Pilomatrix carcinomas have been observed in patients older than 40 years of age, with tendency of local invasion and distant metastases.¹⁸ Histopathologic malignant transformation shows hair-matriculated differentiation as well as an infiltrate pattern with perineural and perivascular invasion, with cell necrosis and mitotic figures.¹⁸ Both pilomatrixoma and pilomatrix carcinoma are related to mutations of the beta-catenin gene (OMIM ID *116806), a signaling protein involved in the development of the pilous follicles.^{11,19}

Nonaggressive excision is usually enough for the treatment of PM. If there is recurrence, a wider excision and a more detailed histopathologic analysis are required.⁵ The spontaneous

regression of PM has never been reported.⁶ In the case reported here, the option was the surgical excision of the tumor, assuring safety margins, due to diagnostic uncertainty and history of lesion recurrence, which is consistent with the literature.^{6,12} The diameter of the lesion is not correlated with the prognosis. Recurrences may be related to incomplete resections,¹¹ as probably occurred in the case described here. The gradual increase of the lesion referred by the patient can be attributed to recurrent inflammations.

Even though that it is considered a rare cutaneous benign neoplasia, pilomatrixoma should be suspected in the differential diagnosis of adnexal giant tumors.

References

1. Malherbe A, Chenantais J. Note sur l'épithéliome calcifié des glandes sébacées. *Prog Med.* 1880; 8: 826.
2. Forbis R Jr, Helwig EB. Pilomatrixoma (calcifying epithelioma). *Arch Dermatol.* 1961; 83: 606-618. PMID: 13700704.
3. Lozzi GP, Soyer HP, Fruehauf J, Massone C, Kerl H, Peris K. Giant pilomatrixoma. *Am J Dermatopathol.* 2007; 29: 286-289. PMID: 17519628.
4. Zaballos P, Llambrich A, Puig S, Malvehy J. Dermoscopic findings of pilomatrixomas. *Dermatology.* 2008; 217: 225-230. PMID: 18663304.
5. Göktay F, Mansur AT, Aydingöz IE, Serdar ZA, Oncel CC, Aker FV. A rare presentation of giant pilomatrixoma located on the back. *Dermatol Surg.* 2007; 33: 596-600. PMID: 17451583.
6. Kovacic M, Rudic M, Nekić I, Lisica-Sikić N, Kranjčec Z, Simurina T. Giant pilomatrixoma (benign calcifying epithelioma of Malherbe) of the neck and face. *Dermatol Surg.* 2007; 33: 340-343. PMID: 17338693.
7. Gilaberte Y, Ferrer-Lozano M, Oliván MJ, Coscojuela C, Abascal M, Lapunzina P. Multiple giant pilomatrixoma in familial Sotos syndrome. *Pediatr Dermatol.* 2008; 25: 122-125. PMID: 18304174.
8. Wood S, Nguyen D, Hutton K, Dickson W. Pilomatrixomas in Turner syndrome. *Pediatr Dermatol.* 2008; 25: 449-451. PMID: 18789085.
9. Krausen AS, Ansel DG, Mays BR Jr. Pilomatrixoma masquerading as a parotid mass. *Laryngoscope.* 1974; 84: 528-535. PMID: 4821511.
10. Zamanian A, Farshchian M, Farshchian M. Clinical and histopathologic study of pilomatrixoma in Iran between 1992 and 2005. *Pediatr Dermatol.* 2008; 25: 268-269. PMID: 18429799.
11. Uchimiya H, Kanekura T, Gushi A, Fukumaru S, Baba Y, Kanzaki T. Multiple giant pilomatrixoma. *J Dermatol.* 2006; 33: 644-645. PMID: 16958813.
12. Yamauchi M, Yotsuyanagi T, Saito T, Ikeda K, Urushidate S, Higuma Y. Three cases of giant pilomatrixoma--considerations for diagnosis and treatment of giant skin tumours with abundant inner calcification present on the upper body. *J Plast Reconstr Aesthet Surg.* 2010; 63: e519-524. PMID: 20080452.
13. Lemos MM, Kindblom LG, Meis-Kindblom JM, Ryd W, Wilén H. Fine-needle aspiration features of pilomatrixoma. *Cancer.* 2001; 93: 252-256. PMID: 11507698.

14. Yoshimura Y, Obara S, Mikami T, Matsuda S. Calcifying epithelioma (pilomatrixoma) of the head and neck: analysis of 37 cases. *Br J Oral Maxillofac Surg.* 1997; 35: 429-432. PMID: 9486450.
15. Lan MY, Lan MC, Ho CY, Li WY, Lin CZ. Pilomatricoma of the head and neck: a retrospective review of 179 cases. *Arch Otolaryngol Head Neck Surg.* 2003; 129: 1327-1330. PMID: 14676160.
16. Dubb M, Michelow P. Fine needle aspiration cytology of pilomatrixoma and differential diagnoses. *Acta Cytol.* 2009; 53: 683-688. PMID: 20014559.
17. Kaddu S, Soyer HP, Wolf IH, Kerl H. Proliferating pilomatricoma. A histopathologic simulator of matrical carcinoma. *J Cutan Pathol.* 1997; 24: 228-234. PMID: 9138114.
18. Bassarova A, Nesland JM, Sedloev T, Danielsen H, Christova S. Pilomatrix carcinoma with lymph node metastases. *J Cutan Pathol.* 2004; 31: 330-335. PMID: 15005691.
19. Moreno-Bueno G, Gamallo C, Pérez-Gallego L, Contreras F, Palacios J. Beta-catenin expression in pilomatrixomas: relationship with beta-catenin gene mutations and comparison with beta-catenin expression in normal hair follicles. *Br J Dermatol.* 2001; 145: 576-581. PMID: 11703283.