

Red scrotum syndrome

Uwe Wollina

Department of Dermatology and Allergology, Academic Teaching Hospital Dresden-Friedrichstadt, Friedrichstrasse 41, 01067 Dresden, Germany.

Corresponding author:

Prof. Dr. med. Uwe Wollina

Department of Dermatology and Allergology, Academic Teaching Hospital Dresden-Friedrichstadt

Friedrichstrasse 41, 01067 Dresden, Germany

E-mail: hwollina-uw@khdf.de

Key words:

differential diagnosis, doxycycline, gabapentine, neurogenic inflammation, red scrotum syndrome

Abstract

Background: Red scrotum syndrome is a rare and chronic disease affecting males in their second half of life. It is characterized by erythema with sharp-borders, no scaling but burning and pain sensations.

Main observations: We report about two cases treated successfully with either doxycycline and tacrolimus or gabapentine.

Conclusion: For practical purposes we suggest to start treating red scrotum syndrome with doxycycline for 2 weeks and use gabapentin as second-line treatment when doxycycline fails. (*J Dermatol Case Rep.* 2011; 5(3): 38-41)

Introduction

The genital skin can be affected by many of the classical inflammatory dermatoses like atopic and irritant dermatitis, psoriasis or ichthyosis.^{1,2} A major differential diagnosis is (bacterial and mycotic) infection.³ In case of treatment failures rare diseases have to be considered. One of this is the Red Scrotum Syndrome (RSS) that affects males in their second half of life and typically runs a chronic course. Delayed diagnosis significantly contributes to ineffective treatments.⁴

Case Reports

CASE 1

A 57-year-old man presented to our department because of persistent redness of the scrotal skin and the base of the penis for about two years. He had suffered from severe itching intertriginous eczema and anal pruritus with anal fissures for more than 20 years. He had been treated with

topical corticosteroids and topical antimycotics. Because of the chronic anal fissuring he was treated with botulinum A injections in the anal sphincter and surgical fissure ectomy. He was taking an oral statin to control hypercholesterolemia for several years.

On examination we found a healthy man with a highly erythematous scrotal skin without any significant scaling, infiltration or lichenification. There was a sharp border to the adjacent unaffected skin (Fig. 1). On the inner thighs striae were present due to long-term steroid application.

A patch test was performed to exclude a contact dermatitis due to topical medical drugs, emulsifiers and preservatives without any positive result. Mycological investigations were negative.

We made the diagnosis of RSS. He was given topical corticosteroid ointments without improvement. Even two courses of systemic corticosteroids did not improve the situation. There was an improvement of the erythema after several weeks due to topical calcineurin inhibitor pimecrolimus. The burning and sometimes itching sensations and the hyperalgesia the patient experienced did not improve much. After 4 months, however there was a relapse that could not

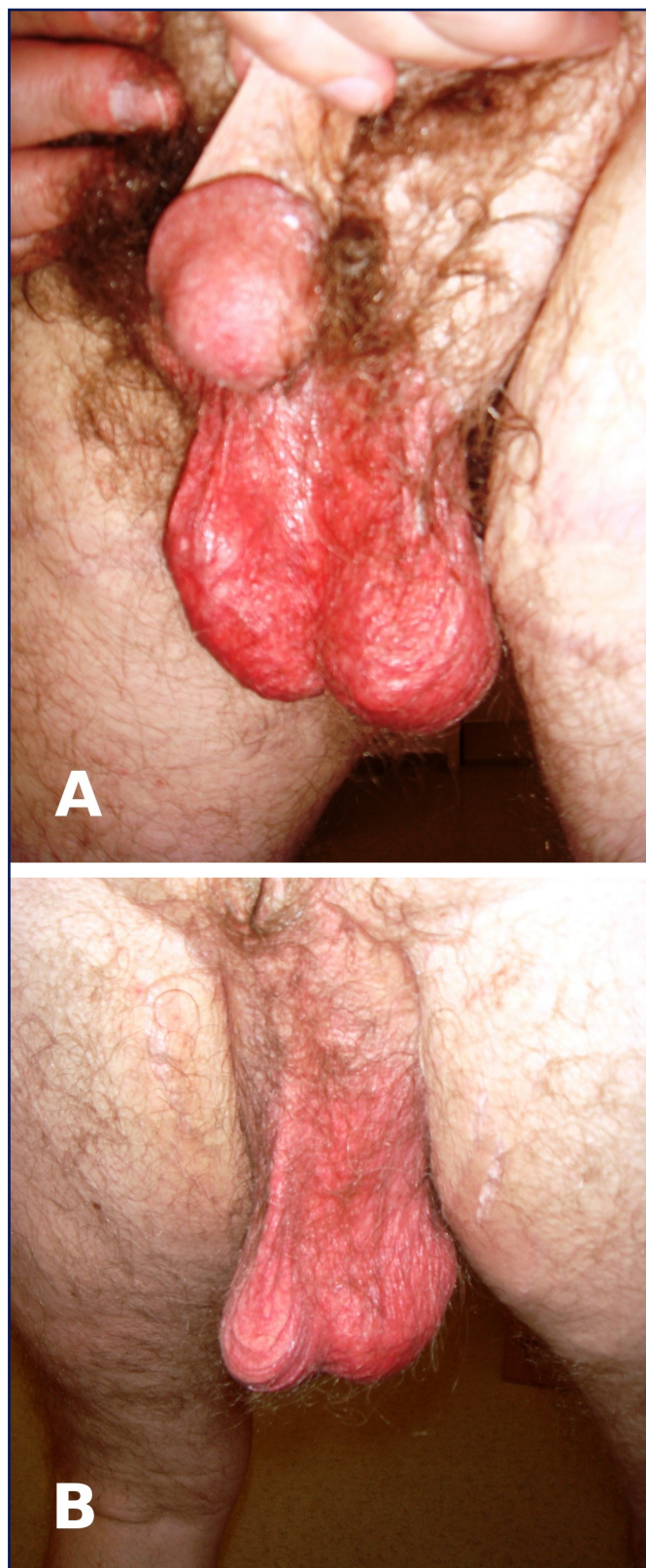


Figure 1

Red scrotum syndrome.

(A) Sharp border between intense erythematous scrotal skin and adjacent skin. No scaling.

(B) Less intense redness on the posterior site.

be controlled by pimecrolimus ointment anymore. Oral doxycycline for 4 weeks did not result in any improvement. Therefore, treatment was switched to oral gabapentine. After 2 weeks a partial remission was noted and further improvement was observed during the next 2 months.

CASE 2

A 60-year-old man presented with burning sensations of scrotal skin for at least 12 months. Topical treatment with corticosteroid ointments so far had not improved his complaints. On examination we found an erythematous scrotal skin without any scaling or scratch marks. The border to the adjacent skin was sharp. He was otherwise healthy. A diagnostic biopsy was taken that was unremarkable beside superficial telangiectasias.

The diagnosis of RSS was made. We started treatment with doxycycline p.o. and tacrolimus 0.1% ointment twice daily with a complete remission of his burning sensations. The redness also improved markedly within 10 days. After 4 weeks treatment was stopped because of complete remission. Both patients reported lower back pain and lumbago in the past but they did not connect these complaints to the scrotal skin affection.

Discussion

RSS is a rare disease characterized by persistent redness (of the anterior half) of the scrotum and may involve the base of the penis as well. It is accompanied by itching, burning and pain sensations.⁴ It can develop after prolonged use of topical corticosteroids like in the red face syndrome. The major symptoms are neurological. Despite looking like eczema on a first glance, morphology and course is quite different. Itch is not the predominant subjective symptom but burning and hyperalgesia. This argues for a possible neurogenic inflammation. Indeed, RSS resembles erythromelalgia.

Thompson's criteria for this complaint are as follows: 1) burning pain of the extremities; 2) pain aggravation by warmth; 3) pain relief by cold; 4) erythema of affected skin; 5) increased temperature of the skin.⁵ A list of differential diagnosis is provided in Table 1.

For decades, there was no effective treatment available. We observed some improvement due to topical calcineurin inhibitors but could not control the burning and pain sensations. Recently, two quite different treatments have been reported with improvement of RSS: oral doxycycline and oral gabapentine.^{6,7}

Doxycycline is a tetracycline with antibiotic and anti-inflammatory effects. It can inhibit matrix metalloproteinases and thereby preventing tissue destruction.⁸

In retrospective evaluation of a group of seven patients, oral doxycycline and steroid abstinence resulted in complete resolution within 2 to 3 months. First improvement was noted within the first two weeks.⁶

Gabapentin is a calcium channel $\alpha 2\text{-}\delta$ ligand effective in the control of neuropathic pain and itch.⁹ The compound

controls hot flashes in prostate cancer patients and erythromelalgia.^{10,11,12} Prevost and English (2007) observed a positive response to gabapentin in a patient with RSS.⁷

We used doxycycline in the first place for patient #1 and observed no improvement. Treatment was switched to oral

gabapentine. After 2 weeks a mild improvement was noted, treatment is continued.

For practical purposes we suggest to start with doxycycline for 2 weeks and use gabapentin as second-line treatment when doxycycline fails.

Table 1. Differential diagnosis of Red Scrotum Syndrome.

	Erythema	Scaling	Pruritus	Excoriations	Borders	Extra-scrotal areas affected	Histopathology	Course
Red Scrotum Syndrome	+++	-	Burning & stinging	None	Sharp	None	Telangiectasias, no inflammatory infiltrate	Chronic
Atopic dermatitis	+++	++	Itching	Yes	Not sharp	Mostly	Spongiotic dermatitis, lymphocytic infiltrate	Undulating
Contact dermatitis	+++++	++	Itching & burning	Yes	Sharp	May be	Spongiotic dermatitis, lymphocytic infiltrate	Acute
Psoriasis	+++	+++++	Sometimes burning	None	Not sharp	Mostly	Acanthosis, hyperparakeratosis, mixed inflammatory infiltrate	Undulating
Ichthyosis	-/+	++	May be	None	Not sharp	Yes	Variable epidermal changes	Chronic
Tinea	+	+	Itching	None	Sharp, centrifugal spread	Mostly	Fungal hyphae	Acute - chronic
Syphilis	+	+	No itch	None	Not sharp	Mostly	Treponemas, plasmacellular infiltrate	Chronic
Langerhans cell histiocytosis	+	+/-	No itch	None but ulcerations	Not sharp	Mostly	Langerhans cells	Chronic

References

1. Kantor GR. What to do about pruritus scroti. *Postgrad Med.* 1990; 88: 95-96, 99-102. PMID: 2235790.
2. Hendry WF, Munro DD. "Wash leather scrotum" (scrotal dermatitis): a treatable cause of male infertility. *Fertil Steril.* 1990; 53: 379-381. PMID: 2137101.
3. Romano C, Ghilardi A, Papini M. Nine male cases of tinea genitalis. *Mycoses.* 2005; 48: 202-204. PMID: 15842338.
4. Fisher BK. The red scrotum syndrome. *Cutis.* 1997; 60: 139-141. PMID: 9314618.
5. Thompson GH, Hahn G, Rang M. Erythromelalgia. *Clin Orthop Relat Res.* 1979; 144: 249-254. PMID: 535232.
6. Abbas O, Kibbi AG, Chedraoui A, Ghosn S. Red scrotum syndrome: successful treatment with oral doxycycline. *J Dermatolog Treat.* 2008; 19: 1-2. PMID: 18608710.
7. Prevost N, English JC 3rd. Case report: red scrotal syndrome: a localized phenotypical expression of erythromelalgia. *J Drugs Dermatol.* 2007; 6: 935-936. PMID: 17941366.
8. Griffin MO, Fricovsky E, Ceballos G, Villarreal F. Tetracyclines: A pleiotropic family of compounds with promising therapeutic properties. Review of the literature. *Am J Physiol Cell Physiol.* 2010; 299: C539-548. PMID: 20592239.
9. Moore RA, Wiffen PJ, Derry S, McQuay HJ. Gabapentin for chronic neuropathic pain and fibromyalgia in adults. *Cochrane Database Syst Rev.* 2011; (3): CD007938. PMID: 21412914.
10. Moraska AR, Atherton PJ, Szydlo DW, Barton DL, Stella PJ, Rowland KM Jr, Schaefer PL, Krook J, Bearden JD, Loprinzi CL. Gabapentin for the management of hot flashes in prostate cancer survivors: a longitudinal continuation Study-NCCTG Trial N00CB. *J Support Oncol.* 2010; 8: 128-132. PMID: 20552926.
11. Hall E, Frey BN, Soares CN. Non-hormonal treatment strategies for vasomotor symptoms: a critical review. *Drugs.* 2011; 71: 287-304. PMID: 21319867.
12. Ceyhan AM, Gurses I, Yildirim M, Akkaya VB. A case of erythromelalgia: good response to treatment with gabapentin. *J Drugs Dermatol.* 2010; 9: 565-567. PMID: 20480803.